

CONGENITAL PANCREATIC CYST, AN INCIDENTAL FINDING IN PREGNANCY: A CASE REPORT FROM THE UPPER WEST REGIONAL HOSPITAL, WA-GHANA

Der E. M.*¹, Ziem B.² and Amesia R.³

¹Department of Pathology, School of Medicine, University for Development studies. Post Office Box TL 1350, Tamale Northern Region, Ghana.

²Lawra Municipal Hospital, Lawra Upper West Region.

³Upper West Regional Hospital, Wa, Upper West Region.

Received date: 03 October 2022

Revised date: 23 October 2022

Accepted date: 13 November 2022

*Corresponding Author: Der E. M.

Department of Pathology, School of Medicine, University for Development studies. Post Office Box TL 1350, Tamale Northern Region, Ghana.

ABSTRACT

The co-existence of true pancreatic cyst in term pregnancy is a rare clinical occurrence. A careful diagnostic workup is required to arriving at the diagnosis. Described here is a case of congenital (true) pancreatic cyst in a 17-years old adolescent girl from the Lawra Municipality in the Upper West Region of Ghana with an intra-abdominal mass co-existing with normal pregnancy that was detected clinically during her booking visit. She was referred to the Upper West Regional hospital for specialist care. An abdominal ultrasound investigation at the regional hospital by the specialist obstetrician revealed a pancreatic cyst. This was carried to term, she had a cesarean delivery to a life baby boy. The pancreatic cyst was resected and histopathological examination confirmed a true pancreatic cyst. The mother and baby were discharged and are currently doing well. **Conclusion:** This case report illustrates the importance of a multidisciplinary approach in effective health care delivery, the role of tertiary referral hospital and the need for specialists in our referral health centres.

KEYWORDS: True pancreatic cyst, pregnancy, adolescence, Upper West Region, Ghana.

INTRODUCTION

Congenital pancreatic cysts are commonly detected in foetuses during the prenatal period by imaging techniques, and may be a component of Beckwith-Wiedemann syndrome (BWS).^[1,2,3,4,5] These lesions are usually incidental findings and accounted for less than 1% of all pancreatic cysts, and commonly in children less than 2 years of age.^[4] However, pseudopancreatic are common in young adults.^[6,7] Embryologically, true pancreatic cysts arise as a developmental abnormality of the pancreatic ductal system.^[8]

Cystic lesions of the pancreas, neoplastic or non-neoplastic, during pregnancy are very rare.^[6,7,10,11] These lesions may be asymptomatic and surgical resection may be postponed until the second trimester.^[10,11] In symptomatic patients, or if there is a concern for intra-uterine growth restriction, urgent surgical resection is performed. With malignant tumours, the benefit of delaying surgery is usually weighed against the risk of maternal disease progression.^[10,11]

Pancreatic pseudocyst in pregnancy, has been documented in the literature,^[6,7] but true pancreatic cyst with term pregnancy is extremely rare in the literature (10,11), more so in Africa and thus, Ghana. We report the first case of a true pancreatic cyst in pregnancy, an incidental finding in a 17-year old adolescent who carried the pregnancy to term and had a live baby boy caesarean section performed as mode of delivery in the Upper West Region of Ghana.

CASE REPORT

Relevant Clinical history

During her booking visit, at gestation age of 19 weeks+1 day on 14th October, 2019 at Lawra Hospital, 17 year old adolescent (G1P0) was found on physical examination by the trained midwife to have a painless mass in the epigastrium which was separate from the uterine fundus. She was referred to the medical officer for further evaluation and the mass was confirmed. She had the baseline haematological parameters checked and document. She was put on the regular ANC drugs; fersolate and folic acid.

She is a junior high school (JHS) form two student, just as her male counterpart. Both of them live in Berwong in the Lawra Municipality in the Upper West Region of Ghana. No previous history of trauma none chronic pancreatitis reported.

On her third ANC visit on 10th February, 2020, at a gestation of 31weeks +1day, the mass has increased in size alongside the pregnancy. But client had no discomfort or respiratory distress or other significant medical condition.

Initial examination findings by medical officer at Lawra

Physical examination by the medical officer during this third ANC visit at the Lawra Municipal hospital revealed an adolescent female with grossly enlarged abdomen and an epigastric bulge, which moves with respiration. A spherical well-defined soft non-tender fluctuant mass of size 12.0cm by 10.0cm was palpated in the epigastrium and this was completely separated from the gravid uterus. SFH of the gravid uterus was 30cm, with cephalic presentation. Foetal heart sounds were present and normal.

Investigations and findings

a. Abdomino-pelvic ultrasound

Live male foetus at 32 weeks+2days.

Placenta was fundal in location.

Liquor volume was adequate.

Massive ascites, liver could not be visible.

b. Blood serology

Hepatitis B and C viral screens were both negative.

Liver function test was requested, but conducted due to lack of funds.

Impression: Ascites in pregnancy R/o Liver Cirrhosis.

She was referred on 24th February, 2020 to obstetric unit of the Upper West Regional Hospital in Wa, the regional capital for specialist review and management.

Second investigation at the regional hospital and plan

Comprehensive scan dated 25th February 2020 revealed a large intra-abdominal and extra-uterine cystic lesion measuring >4256.0cm³ and of a suspected mesenteric origin, displacing the bowels laterally. Pregnancy was grossly normal with a live foetus at EGA 38w+1day and EDD 9th March 2020. Mother had no significant complains.

Risk anticipated: Cyst may potentially rupture spontaneously or as a result of contractions during labour.

Clinical decision: Admit patient the Lawra Hospital (for proximity to home support) and monitor till 40 weeks and refer back to Wa for a planned caesarean section in collaboration with a General Surgeon. In case labour sets in, she was to be referred immediately to Wa.

Clinical progress: Client was admitted on 28th February 2020 to Lawra Hospital. She fared well until 18th March, 2020 when labour set in. She was referred back to Wa, where a caesarean delivery was conducted on 20th March, 2020.

Findings at surgery

Live male baby of weight 3.2kg with an Apgar score of 8/10, 9/10, was delivered.

A huge pancreatic cyst with compression on the left ureter was found, resected and sample sent to the Tamale Teaching hospital for histopathological examination.

Histopathology Examination

Grossly, the sample consisted of a huge resected cystic mass with an attached suture (Figure 1). Slicing through the mass reveals a unilocular cyst filled with deep straw coloured fluid, no palpable lesion seen. The wall was variably thickened. Microscopically, the cyst walls was fibrocollagenous and lined by ciliated pseudostratified columnar epithelium (respiratory epithelium) (**Figure 2**). No malignancy seen Histopathological diagnosis: Pancreatic mass (Resection): True pancreatic cyst.

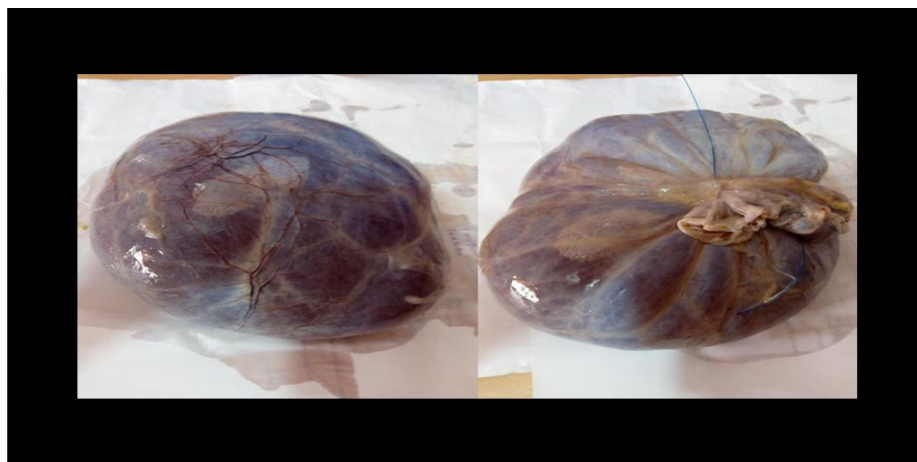

Figure 1: Resected cystic pancreatic mass in a 17-year old female at caeseran.

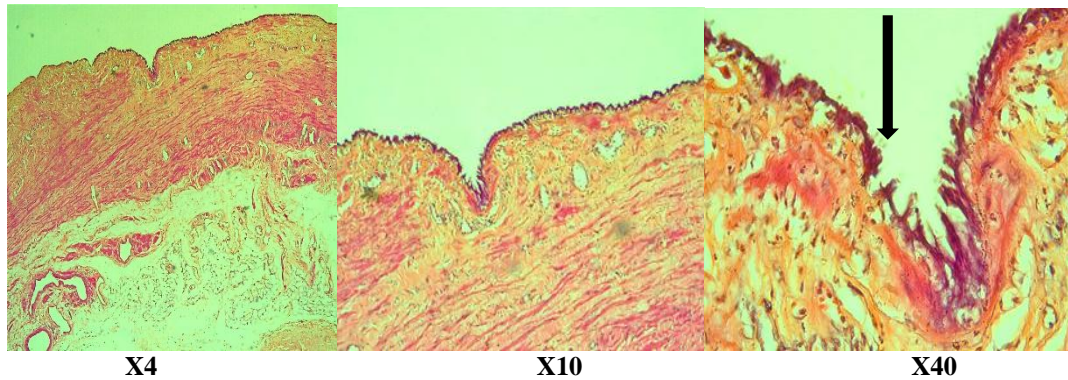


Figure 2: Haematoxylin and eosin (H&E) section of the pancreatic cyst showing fibrocollagenous wall lined by ciliated pseudostratified columnar epithelium; the arrow points to the cilia.

DISCUSSION

Congenital (true) pancreatic cysts are commonly diagnose in foetuses in the prenatal period base on detailed clinical examination, supported by imaging techniques.^[1,2,3,4,5,8,9] Congenital pancreatic cyst in an adult co-existing with a normal pregnancy, carried to term with normal delivery is very rare in the literature.^[10] In Ghana, there is no single published cited in the literature on true maternal pancreatic cyst co-existing with normal pregnancy carried to term.

Described here is a 17-year old pregnant adolescent female (G1P0), with a sonographically confirmed extra-uterine pancreatic cyst that co-existed with the gravid uterus till term (maturity). She had a caesarean section as a mode of delivery to a healthy male neonate. The pancreatic cyst was resected for histopathological examination and this was reported as a true pancreatic cyst. She never had any significant medical complain throughout the pregnancy. After being discharge from the hospital, mother and baby are said to be doing very well till date.

True maternal pancreatic (congenital) cyst co-existing with pregnancy carried to term as mentioned earlier is a very rare pathological entity globally^[10] and this current case report may be the first in the Ghanaian literature. The age at diagnosis (17-years), further offers support to the diagnosis of congenital cyst (developmental)^[8,10] as reported by the pathologist, compared to a pseudocysts reported commonly in adults.^[6,7]

In the antepartum period, sonographic examination revealed a single extra-uterine pancreatic cyst and this was identified and described during the caesarean section delivery and also by the pathologist as a huge solitary intra-abdominal unilocular true pancreatic cyst. The clinico-pathological picture described in this current case report support previous studies that found true congenital pancreatic cysts as solitary, unilocular, non-enzymatic, sterile, fluid-filled cystic lesions originating generally from the pancreas.^[3,5,10]

An important point to note about this case report is the fact that the adolescent female never had any significant health complications of the cyst despite the huge size and therefore carried the pregnancy to term. This may be attributed to the benign and extra-uterine nature of the condition and the fact that most cystic lesions of the pancreas are asymptomatic and are described by previous studies,^[1,2,3,4,7,8,11] as incidental findings during routine antenatal screening, as in the current case report from northern Ghana.

Whether benign or malignant, cystic pancreatic neoplasm in pregnancy are associated with great diagnostic and therapeutic decision making challenges.^[4,6,9,10,11] This fact is perfectly illustrated in the current case report from the Upper West Region of Ghana. For instance, the intra-abdominal mass was first detected incidentally in the adolescent female by the trained midwife during the booking visit. She was referred to the medical officer who confirmed the intra-abdominal mass, his initial ultrasound investigation however, could not detect the origin of the mass. A comprehensive pelvic ultrasound conducted by the specialist Obstetrician at the Upper West Regional Hospital revealed a large intra-abdominal cystic lesion measuring $>4256.0\text{cm}^3$ and of a suspected mesenteric origin, displacing the bowels laterally. Pregnancy was grossly normal with a live foetus at EGA 38w+1day and EDD 9th March 2020. Again, the intra-operatives findings were a live male baby of 3.2kg and an Apgar score of 8/10, 9/10, co-existing with a huge pancreatic cyst compressing on the left ureter. Finally, the mass was confirmed by histopathological examination to be as true (congenital) pancreatic cyst.

What is clear in this current case report, from her booking visit to delivery and subsequent histopathological examination and final diagnosis is the need for multidisciplinary approach in effective health care delivery, the role of effect intra and inter facility referral systems and the need for specialists in our referral health centres.

CONCLUSION

Cystic maternal pancreatic lesions detected during pregnancy require special attention. A thorough diagnostic work-up is mandatory to rule out other neoplastic lesions of the pancreas. Time for delivery and resection the pancreatic lesion has to be individualized depending on symptoms and size of the lesion.

Conflict of Interest

There is no conflict of interest.

Consent to Publish This Case Report

We obtained consent from patients and their relatives.

Funding

The authors received no funding for the work

Author's Contributions

EDM drafted the case reports. BZ and RA provided the clinical history and performed the surgeries. EDM (Pathologist) prepared the tissue and reported the slides. EDM, BZ and RA read through the case reports, edited and approved the final draft for publication.

ACKNOWLEDGEMENTS

We wish to express our profound gratitude to all the staff of Der Medical Diagnosis Centre Limited and the Department of Pathology, Tamale Teaching Hospital. We also would like to thank the patients and their relatives for granting us permission to publish the data.

REFERENCE

- Choi SJ, Kang MC, Kim YH, Lim JS, Lim SC, Chang JH. Prenatal detection of a congenital pancreatic cyst by ultrasound. *J Korean Med Sci.*, 2007; 22: 156-158. doi:10.3346/jkms.2007.22.1.156.
- Waldo Sepulveda, Eduardo Carstens, Jorge Sanchez, Jorge Gutierrez. Prenatal Diagnosis of Congenital Pancreatic Cyst: Case Report and Review of the Literature. *J Ultrasound Med*, 2000; 19: 349–352. 0278-4297/00/\$3.50.
- Fremond B, Poulain P, Odent S, Milon J, Treguier C, Babut JM. Prenatal detection of a congenital pancreatic cyst and Beckwith-Wiedemann syndrome. *Prenat Diagn*, 1997; 17: 276-280.
- Agarwala S, Lal A, Bhatnagar V, Dinda AK, Mitra DK. Congenital true pancreatic cyst: presentation and management. *Trop Gastroenterol*, 1999; 20: 87–882.
- Baker LL, Hartman GE, Northway WH. Sonographic detection of congenital pancreatic cysts in the newborn: report of a case and review of the literature. *Pediatr Radiol*, 1990; 20: 488–4905.
- Eddy JJ, Lynch GE, Treacy DE. Pancreatic pseudocysts in pregnancy: a case report and review of the literature. *J Perinato*, 2003; 23: 69-72. doi:10.1038/sj.jp.7210831
- Gyokeres T. Successful endoscopic resolution of pancreatic pseudocyst in pregnancy. *J Perinatol*, 2004; 24: 270. doi:10.1038/sj.jp.7211059.
- Auringer TS, Ulmer JL, Summer ET, Turner ST. Congenital cyst of the pancreas. *J Pediatr Surg*, 1993; 28: 1570–1571.
- Søreide, J.A., Greve, O.J. & Gudlaugsson, E. Adult pancreatic hemangioma in pregnancy – concerns and considerations of a rare case. *BMC Surg*, 2015; 15: 119. <https://doi.org/10.1186/s12893-015-0106-1>
- Boyd, Casey & Benarroch-Gampel, Jaime & Kilic, Gokhan & Kruse, Edward & Weber, Sharon & Riall, Taylor. Pancreatic Neoplasms in Pregnancy: Diagnosis, Complications, and Management. *Journal of gastrointestinal surgery : official journal of the Society for Surgery of the Alimentary Tract*, 2011; 16: 1064-1071. 10.1007/s11605-011-1797-y.
- MacDonald F, Keough V, Huang W, Michele M. Surgical therapy of a large pancreatic solid-pseudopapillary neoplasm during pregnancy. *Case Reports*, 2014; 2014: bcr2013202259.