

Clinico-Pathological Characteristics of Ovarian Neoplasms in Northern Ghana: A Retrospective Histopathological Review at the Tamale Teaching Hospital (TTH)

Der EM^{1*}, Mukaila A², Asomma K³ Abdulai SA⁴ and Titigah A²

¹Department of Pathology, School of Medicine and Health Sciences, University for Development Studies and Tamale Teaching Hospital, Tamale-Ghana.

²Department of Obstetrics and Gynaecology, Tamale Teaching Hospital, Tamale-Ghana.

³Seven Day Adventist Hospital, northern region, Tamale-Ghana.

⁴Yendi Municipal Hospital, northern region, Tamale-Ghana.

*Correspondence:

Dr Der Muonir Edmund, Department of Pathology, School of Medicine and Health Sciences, University for Development Studies and Tamale Teaching Hospital, Tamale-Ghana, +233208709807; +233248416288.

Received: 29 November 2020; **Accepted:** 22 December 2020

Citation: Der EM, Mukaila A, Asomma K, et al. Clinico-Pathological Characteristics of Ovarian Neoplasms in Northern Ghana: A Retrospective Histopathological Review at the Tamale Teaching Hospital (TTH). *Gynecol Reprod Health*. 2020; 4(4): 1-10.

ABSTRACT

Background: High-quality data on ovarian neoplasms is scarce in Ghana. The situation is even worse in northern Ghana with low numbers of investigative centres. The aim of this retrospective descriptive histopathological review was to describe the spectrum of ovarian neoplasms diagnosed at the Tamale Teaching Hospital (TTH) and the associated clinico-pathological features.

Material and Methods: This was a descriptive retrospective histopathology review in the department of pathology, of the TTH from 1st June, 2013 to 30th June 2020.

Results: The mean age of women diagnosed with ovarian neoplasms was 37.1 ± 16.0 years. There were 121 (54.0%) benign, 98 (43.8%) malignant and 5 (2.2%) borderline lesions ($p < 0.0001$). The main lesions were: germ cell tumours (48.2%), surface epithelial tumours (33.0%), sex cord-stroma tumours (16.1%), metastatic cancers (1.8%) and Burkitt's lymphoma 2 (0.9%). Germ cell tumours were common in women younger than 40-years. All the women presented palpable intra-abdominal masses ($P < 0.0001$). The common germ cell tumours were: mature cystic teratoma (64.8%), immature cystic teratoma (12.0%) and York sac tumour (7.4%). The common surface epithelial tumours were: serous cystadenocarcinoma (31.0%), mucinous cystadenoma (24.3%) and serous cystadenoma (20.3%). The common sex cord-stroma tumours were: adult-type granulosa cell tumour (30.6%), fibroma (27.8%), and juvenile type granulosa cell tumour (16.7%). The common benign lesions were: Mature cystic teratoma (57.8%), mucinous cystadenoma (14.9%), serous cystadenoma (12.4%), and fibroma (8.3%). The common malignant lesions were: serous cystadenocarcinoma (23.5%), immature cystic teratoma (13.3%), adult-type granulosa cell tumour (11.2%), York sac (8.2%) and struma ovarii (6.1%).

Conclusion: The common histological subtypes of ovarian tumours were: germ cell tumours, surface epithelial tumours, sex-cord stroma tumours, metastatic cancers and Burkitt's lymphoma. Significant proportion of the lesions were malignant, an important finding. This study may be useful in future for further study of ovarian neoplasms in northern Ghana.

Keywords

Ovarian tumours, Spectrum, Clinico-pathological features, Tamale, Northern, Ghana.

Introduction

Ovarian neoplasms are common causes of morbidity and mortality globally [1]. The situation is however worse in developing countries where these cancers are major causes of cancer related deaths [1]. Neoplasms of the ovaries affect all age groups across the world, although some are age specific [2,3]. The initial clinical symptoms are generally non-specific, thus most women are diagnosed only at an advanced stage of the disease with large intra-abdominal masses, abdominal distension and systemic complications and this thus result in poor prognosis [4]. Ovarian neoplasms are classified based on the probable tissue of origin by World Health Organization (WHO) into the following categories together with their relative proportions: surface epithelial (65%), germ cell (15%), sex cord-stromal (10%), metastases (5%), and miscellaneous 5% [5].

In Ghana, ovarian tumours contribute significantly to the cancer burden and equally account for significant proportions of cancer related morbidity and mortality [6-10]. High-quality cancer data is scarce in Ghana, more so on ovarian neoplasms. This is partly due to the lack of a population based cancer registry in Ghana; an institution which is supposed to provide the basic data needed for planning and implementing evidence-based cancer control programmes. The situation is even worse in northern Ghana with low numbers of investigative centres. The aim of this retrospective descriptive histopathological review was to describe the spectrum of ovarian neoplasms diagnosed at the Tamale Teaching Hospital (TTH) and the associated clinico-pathological features.

Materials and Methods

Study Design

A descriptive retrospective study was conducted from 1st June 2013 to 30th June, 2020.

Study Site

The study was conducted in the Department of Pathology, Tamale Teaching Hospital (TTH), and the largest referral hospital in northern Ghana. This Department receives histopathological specimens from its catchment area and beyond, particularly, neighboring Burkina Faso.

Data collection, entry and Analysis

All the histology request forms and the histology reports of all ovarian specimens submitted to the department during the period of study (1st June, 2013 to 30th May, 2020) were retrieved and cases of neoplastic ovarian lesion extracted. The corresponding slides and where necessary, the paraffin embedded blocks, were reviewed by the pathologist.

Data were collected on the age at presentation and relevant clinical history (symptoms, duration, laterality and type of operation). We

also collected data of the histopathological characteristics: size of the ovary, calcifications, haemorrhage, necrosis, histological diagnosis, histological grade, the TNM stage, the FIGO stage, omental and other organs/tissue spread and the presence of ascites. Furthermore, data was collected on women with bilateral tumours of the ovaries and also other tumours.

The data was entered into a statistical database and analysed using SPSS software version 23.0 (Chicago). Fisher's exact test was used where applicable to compare features of malignant and benign ovarian neoplasms. The results were presented in bar charts and frequency tables.

In this study, ovarian neoplasms were classified according to World Health Organization (WHO) classification which is based on the probable tissue of origin into: surface epithelial, germ cell, sex cord-stromal, metastases, and miscellaneous [b]

Inclusion criteria

All histologically confirmed ovarian neoplasms diagnosed during the period of study.

Exclusion criteria

All cases of poorly fixed specimens and those with incomplete records were excluded. Non-neoplastic lesions and tumour-like conditions were excluded from the study.

Results

Major categories of neoplastic ovarian lesions and their clinical presentations

A total of 224 neoplastic lesions of the ovary were reviewed and confirmed. The main neoplastic lesions were: germ cell tumours 108 (48.2%), surface epithelial tumours 74 (33.0%), sex cord-stroma tumours 36 (16.1%), metastatic cancers 4 (1.8%) and Burkitt's lymphoma 2 (0.9%) (Table 1). There were 121 (54.0%) benign lesion, compared to 98 (43.8%) malignant lesion (P=0.0354), with 5 (2.2%) borderline lesions forms.

Their ages ranged from 3 – 80 years, with a mean of 37.1 ± 16.0 and a modal age group of 20 – 29 years (29.0%), (Figure 1). A total of 133 (61.6%) of the cases were younger than 40 years, ($p < 0.0001$) (Table 1).

The commonest (87.9%) primary symptom was pelvic mass. For the 85 females with additional complains, majority (84.7%), had abdominal distension / ascites. The duration of ovarian lesions at presentation varied from 1 to 120 months, with a mean of 30.5 ± 20.3 . Approximately 51.7% of the females presented within 12 months of onset of illness. The sizes of neoplastic ovarian lesions varied from 0.5 – 42 cm, with a mean of 13.6 ± 6.8 . Neoplastic lesions commonly involved the right ovary (46.4%) (Table 1). Surface epithelial and sex-cord stroma tumours were commonly diagnosed in hysterectomy specimens (Figure 1).

		Major groups of neoplastic ovarian lesions						Total (%)			
		Surface epithelia tumour	Sex cord stromal tumour	Germ cell tumour	Metastatic tumour	Lymphoma					
Age group (years) N=224	≤9	1	0	1	0	1	3 (1.4)				
	10 -19	2	3	13	0	1	19 (8.5)				
	20 -29	19	6	38	2	0	65 (29.0)				
	30 -39	16	8	25	2	0	51 (22.8)				
	40 -49	12	8	17	0	0	37 (16.5)				
	50 -59	12	8	7	0	0	27 (12.1)				
	60 -69	8	1	4	0	0	13 (5.8)				
	≥70	4	2	3	0	0	9 (4.0)				
Total		74	36	108	4	2	224 (100.0)				
Mean age (years)		42.2 ± 16.0		40.9 ± 16.1		33.1 ± 15.0		31 ± 8.1		13 ± 5.6	
Primary Symptom N=224	Abdominal and pelvic mass	63	33	96	3	2	197 (87.9)				
	Abdominal pain	7	2	6	1	0	16 (7.1)				
	Bleeding per vagina	3	0	5	0	0	8 (3.6)				
	Infertility	1	1	1	0	0	3 (1.4)				
Secondary Symptom N=85	Abd distension / ascites	31	4	32	4	1	72 (84.7)				
	Anaemia	2	0	0	0	0	2 (2.4)				
	Dysmenorrhoea	1	0	1	0	0	2 (2.4)				
	Tubal pregnancy	0	0	3	0	0	3 (3.5)				
	Retention of urine	1	0	0	0	0	1 (1.2)				
	Weight loss	1	0	1	0	0	2 (2.4)				
	Early satiety	1	0	0	0	0	1 (1.2)				
	Intestinal obstruction	1	0	0	0	0	1 (1.2)				
Precocious puberty	0	1	0	0	0	1 (1.2)					
Duration (Months) N=224	1-6	9	5	18	2	1	35 (15.6)				
	7-12	9	2	19	0	1	31 (13.8)				
	13 - 24	13	10	26	1	0	50 (22.3)				
	25 - 36	16	7	20	1	0	44 (19.6)				
	37 - 48	10	8	13	0	0	31 (13.8)				
	≥48	17	4	12	0	0	33 (14.7)				
Mean duration (moment)		34.7 ± 20.9		34.4 ± 23.2		27.4 ± 18.0		15.5 ± 17.4		9.0 ± 4.2	
Size of neoplastic ovary (cm) N=224	≤4.9	6	3	4	0	0	13 (5.8)				
	5 - 9.9	17	6	29	3	0	55 (24.6)				
	10 - 14.9	17	9	44	0	0	70 (31.3)				
	15 - 19.9	16	10	16	1	1	44 (19.6)				
	≥20	18	8	15	0	1	42 (18.8)				
Mean size (cm)		14.6 ± 8.6		14.4 ± 6.4		12.8 ± 8		10.5 ± 5.8		20.3 ± 2.5	
Laterality N=224	Left ovary	27	10	45	1	0	83 (37.1)				
	Not stated	6	0	5	0	0	11 (4.9)				
	Right ovary	33	23	48	1	0	104 (46.4)				
	Bilateral	8	4	10	2	2	26 (11.6)				

Table 1: Symptoms, duration, type of surgery, size of ovary and laterality of neoplastic lesions.

Histological spectrum of benign and malignant neoplastic lesions

The common benign lesions were: Mature cystic teratoma (57.8%), mucinous cystadenoma (14.9%), serous cystadenoma (12.4%), and fibroma (8.3%). The common malignant lesions were: serous cystadenocarcinoma (23.5%), immature cystic teratoma (13.3%), adult-type granulosa cell tumour (11.2%), York sac (8.2%) and struma ovarii (6.1%) (Table 2).

Germ cell tumours (n=108)

The common histological subtypes of germ cell tumours were: mature cystic teratoma (64.8%), immature cystic teratoma

(12.0%), York sac tumour (7.4%), stroma ovarii (5.6%) and dysgerminoma (3.7) (Table 3). The ages of females diagnosed with germ cell tumours ranged from 7-75 years, with a mean of 33.1 ± 15.0. Majority 77 (71.3%; p<0.0001) were younger than 40 years (Table 1). For the subtypes of germ cell tumours, IMCT and dysgerminoma were common in females younger than 30 years old (Table 3). The commonest presentation was a pelvic mass in all the subtypes (Table 3). The duration of symptoms at presentation was 27.4 ± 18.0, and a total of 63 (58.3%) of females presented within 2-years from the onset of the illness (P=0.0205), (Tables 1and3). The sizes of the germ cell tumours were generally large and ranged from 2.5-30cm, with a mean of 12.8 ± 5.7cm (Table 1). Majority

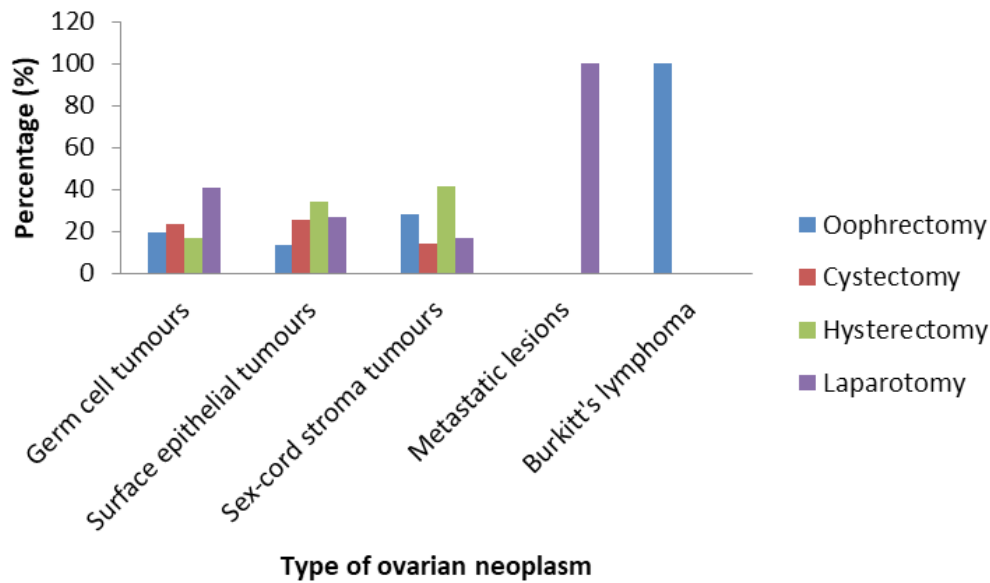


Figure 1: Types of ovarian specimens

Type of ovarian lesion	Frequency (n)	Percentage (%)
Benign lesions		
Mature cystic teratoma	70	57.8
Mucinous cystadenoma	18	14.9
Serous cystadenoma	15	12.4
Fibroma	10	8.3
Thecoma	3	2.5
Dermoid cyst	3	2.5
Oncocytoma	1	0.8
Atypical naevus	1	0.8
Total	121	100.0
Malignant lesions		
Serous cystadenocarcinoma	23	23.5
Immature cystic teratoma	13	13.3
Adult-type granulosa cell tumour	11	11.2
York sac tumour	8	8.2
Struma ovarii	6	6.1
Mucinous cystadenocarcinoma	5	5.1
Juvenile granulosa cell tumour	5	5.1
Malignant Brenner's tumour	4	4.1
Spindle cell sarcoma	5	5.1
Dysgerminoma	4	4.1
Metastatic lesions	4	4.1
Endometrioid carcinoma	3	3.1
Squamous cell carcinoma in mature cystic teratoma	3	3.1
Burkitt's lymphoma	2	2.0
Malignant Brenner's tumour	1	1.0
Sertolig cell tumour	1	1.0
Total	98	100.0
Borderline lesions		
Mucinous	2	40.0
Serous	1	20.0
Brenner's	1	20.0
Endometrioid	1	20.0
Total	5	100.0

Table 2: Histological spectrum of neoplastic lesions: benign and malignant tumours.

	Germ cell tumours (n/%0)							
	MCT	IMCT	Stroma ovarii	York sac	Dysgerminoma	SCC in MCT	Dermoid cyst	Atypical naevus
Age groups (years)								
0 - 9	1	0	0	0	0	0	0	0
10 - 19	6	3	1	1	3	0	0	0
20 - 29	24	6	2	4	1	0	0	1
30 - 39	19	2	1	0	0	0	2	0
40 - 49	15	1	1	0	0	0	0	0
50 - 59	3	1	1	3	0	0	0	0
60 - 69	0	0	0	0	0	2	1	0
≥70	2	0	0	0	0	1	0	0
Total	70 (64.8)	13 (12.0)	6 (5.6)	8 (7.4)	4 (3.7)	3 (2.8)	3 (2.8)	1 (0.9)
Mean age (years)	32.7 ± 13	26.8 ± 12.0	37.2 ± 14.3	35.1 ± 1	16.3 ± 6.3	68 ± 8.2	44.3 ± 19.9	26.0
Primary symptoms								
Abd/pelvic mass	60 (85.8)	13 (100.0)	6 (100.0)	7 (87.5)	3 (75.0)	3 (100.0)	3 (100.0)	1 (100.0)
Abd pain	5 (7.1)	0 (0.0)	0 (0.0)	1 (12.5)	1 (25.0)	0 (0.0)	0 (0.0)	0 (0.0)
Bleeding PV	5 (7.1)	0 (0.0)	0 (0.0)	0 (0.0)	0 (0.0)	0 (0.0)	0 (0.0)	0 (0.0)
Secondary symptoms								
Abd distension	20 (83.3)	4 (100.0)	3 (100.0)	2 (100.0)	2 (66.7)	-	-	-
Dysmenorrhea	1 (4.2)	-	-	-	-	-	-	-
Tubal gestation	3 (12.5)	-	-	-	1 (0.0)	-	-	-
Duration of symptoms (years)								
≤2	44 (62.9)	7 (53.8)	3 (50.0)	4 (50.0)	2 (50.0)	1 (25.0)	1 (25.0)	1 (100.0)
>2	36 (37.1)	6 (46.2)	3 (50.0)	4 (50.0)	2 (50.0)	2 (57.0)	2 (75.0)	0 (0.0)
Size of primary tumour (cm)								
≤9.9	57 (81.4)	5 (38.5)	6 (100.0)	2 (25.0)	3 (75.0)	0 (0.0)	3 (100.0)	1 (100.0)
≥10	9 (18.6)	8 (61.5)	0 (0.0)	6 (75.0)	1 (25.0)	3 (100.0)	0 (0.0)	0 (0.0)
Mean size	11.4 ± 4.9	19.1 ± 6.9	10.6 ± 1.6	17.4 ± 3.5	11 ± 3.7	8.3 ± 4.5	19 ± 3.4	-
Laterality								
Right	32 (45.2)	5 (38.5)	2 (33.3)	6 (75.0)	1 (25.0)	1 (33.3)	1 (33.3)	-
Left	30 (62.9)	6 (46.2)	2 (33.3)	1 (12.5)	2 (50.0)	2 (66.7)	2 (66.7)	-
bilateral	5 (7.1)	1 (7.7)	2 (33.3)	0 (0.0)	1 (25.0)	0 (0.0)	0 (0.0)	-
Not stated	2 (4.3)	1 (7.7)	0 (0.0)	1 (12.5)	0 (0.0)	0 (0.0)	0 (0.0)	1 (100.0)

Table 3: Clinico-pathological characteristics of germ cell tumours of the ovary.

75 (69.4%; $P < 0.001$) were 10.0cm and above (Table 1). Large size tumours were common in immature cystic teratomas and York sac tumours (Table 3).

Surface epithelial tumours (n=74)

The common histological subtypes of surface epithelial tumours were: serous cystadenocarcinoma (31.0%), mucinous cystadenoma (24.3%), serous cystadenoma (20.3%), mucinous cystadenocarcinoma (6.8%), and malignant Brenner's tumour (4.4%) (Table 4). The ages of females diagnosed with germ cell tumours ranged from 11-80 years, with a mean of 42.2 ± 16.0 . A total of 38 (51.4%; $P = 0.6172$) were younger than 40 years old (Table 1). For the subtypes of surface epithelial tumours; serous cystadenoma, mucinous cystadenocarcinoma and the borderline tumours were common in females younger than 30 years of age (Table 4). The commonest presentation was a pelvic mass in all the subtypes (Table 4). The mean duration of surface epithelial tumours at presentation was 34.7 ± 20.9 , a total of 43 (58.1%) of females presented after 2-years of onset of the illness ($P = 0.0702$) (Tables 1 and 4).

The sizes of surface epithelial tumours varied between 0.5 - 42 cm, with a mean of 14.6 ± 8.5 cm (Table 1). Majority 51 (68.9%; $P < 0.0001$) were 10.0cm and above (Table 1). Large size tumours were common with mucinous and endometrioid subtypes (Table 4).

Sex cord-stroma tumours (n = 36)

The common histological subtypes of sex cord-stroma tumours were: adult-type granulosa cell tumour (30.6%), fibroma (27.8%), and juvenile type granulosa cell tumour (16.7%), (Table 5). The age range for sex cord-stroma tumours was 17-77 years, with a mean of 40.9 ± 16.1 . A total of 19 (52.8%) were aged 40 years and above (Table 1). The commonest presentation was a pelvic mass in all the subtypes (Table 5). The mean duration of sex cord-stroma tumours at presentation was 34.4 ± 23.2 , a total of 19 (52.8%) of females presented after 2 years of onset of illness ($P = 0.8139$), (Tables 1 and 5). The sizes of sex-cord stroma tumours varied from 2.1 – 30.0cm, with a mean of 14.4 ± 6.4 cm (Table 1). Majority 27 (75.0%; $P < 0.001$) were 10.0cm and above (Table 1). Large size tumours were common in juvenile type granulosa cell tumour and thecoma subtypes (Table 5).

	Surface cell epithelial tumours (n/%)							
	Serous ca	Mucinous cystadenoma	Serous cystadenoma	Mucinous ca	Malig Brenner's tumour	Endometrioid Ca.	Borderline tumours	Oncocytoma
Age groups (years)								
0 - 9	1	0	0	0	0	0	0	0
10 - 19	0	1	1	0	0	0	0	0
20 - 29	4	3	7	2	0	0	2	1
30 - 39	2	7	4	2	1	0	0	0
40 - 49	4	3	2	1	0	1	1	0
50 - 59	7	1	1	0	0	1	2	0
60 - 69	4	3	0	0	0	1	0	0
≥70	1	0	0	0	3	0	0	0
Total	23 (31.0)	18 (24.3)	15 (20.3)	5 (6.8)	4 (5.4)	3 (4.0)	5 (6.8)	1 (1.4)
Mean age (years)	48.5 ± 15.3	40.1 ± 13.8	31.9 ± 10.5	32.2 ± 7.4	65 ± 23.0	55 ± 7.2	38.8 ± 14.9	-
Primary symptoms								
Abd/pelvic mass	20 (87.0)	15 (83.3)	12 (80.0)	5 (100.0)	2 (50.0)	3 (100.0)	3 (100.0)	1 (100.0)
Abd pain	5 (7.1)	2 (11.1)	2 (13.3)	0 (0.0)	0 (0.0)	0 (0.0)	0 (0.0)	0 (0.0)
Bleeding PV	3 (13.0)	1 (5.6)	1 (6.7)	0 (0.0)	1 (25.0)	0 (0.0)	0 (0.0)	0 (0.0)
Infertility	0 (0.0)	0 (0.0)	0 (0.0)	0 (0.0)	1 (25.0)	0 (0.0)	0 (0.0)	0 (0.0)
Secondary symptoms								
Abd distension	15 (83.3)	5 (83.3)	6 (85.0)	3 (100.0)	2 (66.7)	2 (66.7)		1 (100.0)
Anaemia	2 (11.1)	-	-	-	-	-	-	-
Dysmenorrhea	1 (4.2)	-	-	-	-	-	-	-
Tubal gestation	3 (12.5)	-	-	-	-	-	-	-
Weight lost	1 (5.6)	1 (16.7)	1 (15.0)		1 (0.0)	1 (33.3)		
Duration of symptoms (years)								
≤2	8 (37.9)	9 (50.0)	6 (40.0)	2 (40.0)	2 (50.0)	0 (0.0)	3 (60.0)	1 (100.0)
>2	15 (65.1)	9 (50.0)	9 (60.0)	3 (60.0)	2 (50.0)	3 (100.0)	2 (40.0)	0 (0.0)
Size of primary tumour (cm)								
≤9.9	13 (56.5)	3 (16.7)	8 (53.3)	0 (0.0)	2 (50.0)	0 (0.0)	1 (20.0)	0 (0.0)
≥10	10 (43.5)	15 (83.3)	7 (46.7)	5 (100.0)	2 (50.0)	3 (100.0)	4 (80.0)	1 (100.0)
Mean size	10.4 ± 8.4	16.3 ± 6.5	15.3 ± 8.6	22.4 ± 11.2	11 ± 3.8	21.3 ± 9.1	16.6 ± 6.9	-
Laterality								
Right	10 (43.5)	8 (44.4)	6 (40.0)	3 (60.0)	1 (25.0)	2 (66.7)	2 (40.0)	1 (100.0)
Left	6 (26.1)	8 (44.4)	7 (46.7)	1 (20)	3 (75.0)	0 (0.0)	2 (40.0)	-
bilateral	2 (8.7)	1 (5.6)	2 (13.3)	1 (20.0)	0 (0.0)	1 (33.3)	1 (20.0)	-
Not stated	5 (21.5)	1 (5.6)	0 (0.0)	0 (0.0)	0 (0.0)	0 (0.0)	0 (0.0)	-

Table 4: Clinico-pathological characteristics of surface epithelial cell tumours of the ovary.

Metastatic lesions

There were 4 cases of metastatic lesions, with a mean age of 31 ± 8.1 years. All were within 20 – 39 years. A total of 3 (75.0%) presented with pelvic masses, while 1 (25.0) had abdominal pain. A total of 3 (75.0%) presented within two years, while 1 (25.0%) presented after two years. The subtypes were; metastatic gastric adenocarcinoma (Krukenberg tumour) 2 (50.0%), mucinous carcinoma 1 (25.0%) and endometrial carcinoma 1 (25.0%).

Burkitt's lymphoma

There were two cases of Burkitt's lymphoma involving 9 and 17 year old females respectively. Both presented within 12 months with huge (20.0cm) bilateral masses.

Discussion

The current descriptive retrospective study was conducted in the department of pathology of the TTH, the largest referral hospital in northern Ghana, and being the first in this part of the world, it provided significant information regarding the clinico-pathological characteristics of ovarian neoplasms among the study population.

The common ovarian neoplasms in descending of magnitude in this study were: germ cell tumours (46.8%), surface epithelial tumours (33.0%), sex-cord stroma tumours (17.4%), metastatic cancers (1.8%) and Burkitt's lymphoma (0.9%). This pattern is at variance with that reported by Mondal et al., [11], Lee-Jones et al., [4], Ahmed et al., [15] and that of the WHO, in 2019 [5]. For

Sex-cord stroma tumours (n%)							
	Adult-type GCT	Juvenile type GCT	Fibroma	Thecoma	Sarcomas	Malignant GCT	Sertolig cell tumour
Age groups (years)							
10 - 19	0	1	2	0	0	0	0
20 - 29	0	2	2	0	0	1	1
30 - 39	1	2	3	1	2	0	0
40 - 49	4	1	1	0	1	0	0
50 - 59	5	0	1	1	1	0	0
≥70	1	0	1	1	0	0	0
Total	11 (30.6)	6 (16.7%)	10 (27.8)	3 (6.8)	4 (5.4)	1 (4.0)	1 (6.8)
Mean age (years)	51 ± 11.6	29.3 ± 12.2	36 ± 19.5	54.3 ± 15.1	40 ± 8.6	-	-
Primary symptoms							
Abd/pelvic mass	11 (100.0)	6 (100.0)	8 (80.0)	2 (66.7)	2 (50.0)	1 (100.0)	1 (100.0)
Abd pain	0 (0.0)	0 (0.0)	2 (20.0)	0 (0.0)	0 (0.0)	0 (0.0)	0 (0.0)
Bleeding PV	0 (0.0)	0 (0.0)	0 (0.0)	0 (0.0)	1 (25.0)	0 (0.0)	0 (0.0)
Infertility	0 (0.0)	0 (0.0)	0 (0.0)	1 (33.3)	1 (25.0)	0 (0.0)	0 (0.0)
Secondary symptoms							
Abd distension	-	1 (100.0)	2 (100.0)	3 (100.0)	2 (66.7)	1 (100.0)	-
Weight lost	-	-	-	-	1 (0.0)	-	-
Precocious puberty	-	-	-	-	-	-	1 (100.0)
Duration of symptoms (years)							
≤2	2 (18.2)	5 (83.3)	8 (80.0)	2 (40.0)	2 (50.0)	0 (0.0)	0 (0.0)
>2	9 (81.8)	1 (16.7)	2 (20.0)	3 (60.0)	2 (50.0)	1 (100.0)	1 (100.0)
Size of primary tumour (cm)							
≤9.9	2 (18.2)	2 (33.3)	6 (60.0)	0 (0.0)	2 (50.0)	0 (0.0)	0 (0.0)
≥10	9 (81.8)	4 (66.7)	4 (40.0)	5 (100.0)	2 (50.0)	1 (100.0)	1 (100.0)
Mean size	13.6 ± 5.6	16 ± 9.6	11.3 ± 6.2	22.4 ± 11.2	11 ± 3.8	-	-
Laterality							
Right	7 (63.6)	3 (50.0)	6 (60.0)	3 (60.0)	1 (25.0)	1 (100.0)	1 (100.0)
Left	4 (36.4)	1 (16.7)	3 (30.0)	1 (20)	3 (75.0)	0 (0.0)	0 (0.0)
bilateral	0 (0.0)	2 (33.3)	1 (10.0)	1 (20.0)	0 (0.0)	0 (0.0)	0 (20.0)

Table 5: Clinico-pathological characteristics of sex-cord stroma tumours of the ovary.

instance, Mondal et al., found germ cell tumours as the second common ovarian neoplasms in their study and this accounted for 23.1% [11], much lower than the 46.8% in the current study. Again, the relative proportions of ovarian neoplasms reported in 2019 by WHO were: surface epithelial (65%), germ cell (15%), sex cord-stromal (10%), metastases (5%), miscellaneous (5%) [5] and this also differs from that reported in our study. Similarly, in Saudi Arabia, Abdullah et al., found 61.0% of ovarian tumours were surface epithelial in origin, 28.0% were germ cell in origin, 7.6% were sex cord stromal tumour and 3.4% were metastatic [12]. Furthermore, in Pakistan, a study conducted by Ahmad et al., (2000) found surface epithelial tumour to be the most common type of ovarian tumour (63.50%), followed by germ cell tumours (27.13%) and sex cord-stromal tumours (5.84%) [14]. However, the current findings support previous studies in Accra Ghana [6,7], Lagos Nigeria [15] and among African Americans in the United States of America [16,17] that found germ cell tumours as the commonest ovarian neoplastic lesions. For instance, Kafui et al., reported that germ cell tumours accounted for 41.9% in their study in Accra [8], Onyiaorah et al., in Lagos [15] reported 52.7%, while Moorman et al., years ago reported germ cell tumours prevalence of 52.0% among South Africa blacks [17]. This seems to suggest that

there is variation in the relative proportions of ovarian neoplasms across regions, countries and largely the globe. Thus we think the relative proportions of ovarian neoplasms depends largely on the geographical location of the study and the sample size [15,18,19].

In this current study a significant proportion of the lesions were malignant. For instance, benign lesions accounted for 54.0% compared to 43.8% for the malignant counterparts (P=0.0354) and 2.2% borderline tumours. This differs from the 80.3% benign and the 19.7% malignant ovarian tumours reported by Onyiaorah et al., in Lagos, Nigeria [15]. It is similarly at variance with 85.0% benign, 13.4% malignant and 1.6% borderline tumours reported by Ahmed et al., in Bangladesh [12]. In Saudi Arabia, Abdullah et al., found 61.0% of ovarian tumours to be benign, 5.2% borderline and 22.0% malignant [13]. In Nepal, Vaidya et al., reported 80.72% of ovarian tumours as benign, with 3.58% were borderline and 15.70% malignant tumours [19]. In Pakistan Ahmad et al. found 59.18% ovarian tumours were benign, 3.27% were border line and 37.54% were malignant [14].

The common benign tumours in this study were: mature cystic teratoma (57.8%), mucinous cystadenoma (14.9%), serous

cystadenoma (12.4%), and fibroma (8.3%). This is in line with studies conducted in Ghana [7,8] and Nigeria [15] that found mature cystic teratoma as the commonest benign ovarian neoplasm. However, the pattern reported in this current study differs from reports of studies in Bangladesh [12], Saudi Arabia [13], Pakistan [14], Nepal [19] and India [20]. For instance, Tejeswini et al., in India reported the relative proportions of benign ovarian neoplasms as: serous cystadenoma (65.0%), mature cystic teratoma (21.7%), mucinous cystadenoma (8.3%) and fibroma (1.8%) [20].

In this current study in Tamale Ghana, the common malignant tumours were: serous cystadenocarcinoma (23.5%), immature cystic teratoma (13.3%), adult-type granulosa cell tumour (11.2%), York sac (8.2%) and struma ovarii (6.1%). This is similar to reports from Bangladesh [15], Nepal [19] and India [20]. In Nepal, Vaidya et al., reported the pattern as: serous cystadenocarcinoma (29.8%), immature cystic teratoma (15.8%), metastatic lesions (10.5%), endometrioid carcinoma (8.8%) and mucinous cystadenocarcinoma (7.0%) [19]. Our findings however differ from results of studies in Ghana [8] and India [21]. For instance, Sharma et al., quoted the following percentages: endometrioid carcinoma (38.9%), serous cystadenocarcinoma (16.7%), mucinous cystadenocarcinoma (11.1%), metastatic lesions (11.1%) and immature cystic teratoma (5.6%) [21].

The mean age of females diagnosed with ovarian neoplasms was 37.1 ± 16.3 , and that 61.6% were younger than 40-years of age ($P < 0.0001$). The age characteristics of the current study differ from the mean of 46.4 years quoted in Nkyekye study in Accra Ghana [7]. Almost all the women with ovarian neoplasms presented late with large palpable pelvic masses. Also, a significant proportion of them had associated ascites. Late presentation of female with ovarian neoplasms has documented in Ghana [7,8], Nigeria [15] and India [21], and our findings were therefore not a surprise. This picture may be due to the fact that early lesions are either asymptomatic or non-specific, and may only be detected at an advanced stage or during medical screening.

The neoplastic lesions in this study significantly involved the right ovary ($P = 0.039$), with 11.6% being bilateral. The laterality of ovarian neoplasms reported in this study are in line with 11.23% by Ahmad et al., in Bangladesh [12] and 11.29% reported by Sharma et al., (2014) in India [21]. The current value of bilateral involvement is much higher than 5.40% and 4.52% reported by Tejeswini et al., (2013) [20] and Misra et al., in their individual studies [20,22] respectively.

The common epithelial neoplasms were: serous cystadenocarcinoma (31.9%), mucinous cystadenoma (23.6%), serous cystadenoma (20.8%) and mucinous cystadenocarcinoma (6.9%). This differs from previous studies that reported the predominant tumour of surface epithelial origin as benign mucinous cystadenoma [4,8,11]. Also, in this study serous tumours contributed the larger proportion of epithelial tumours, and this is in line with previous studies [12,18]. Furthermore, serous cystadenocarcinoma was equally the commonest malignant epithelial tumour similar to

that of a study in the United States of America [18]. The other malignant epithelial tumours were: Malignant Brenner's tumour (14.3%) mucinous cystadenocarcinoma (11.4%) and endometrioid adenocarcinoma (8.6%). These relative proportions support previous studies in Ghana [8], India [12] and West Africa [23,24].

The common histological subtypes of germ cell tumours were: mature cystic teratoma (69.6%), immature cystic teratoma (11.8%) and York sac tumour (6.9%). Mature cystic teratoma being the predominant germ cell tumour is in line with previous studies [8] in Ghana and India [12]. The commonest malignant germ cell tumour in this study was immature cystic teratoma (11.1%). This however differs from studies in Ghana [8], India [12] and the United States of America [17], which reported dysgerminoma as the predominant malignant germ cell tumour.

Sex-cord stroma tumours constituted 17.4% of all the neoplastic ovarian tumours in the current study. This is higher than value reported in Ghana [8] and other parts, in the world [11,24,25]. The first three common histological subtypes were: adult-type granulosa cell tumour (30.6%), fibroma (27.8%) and juvenile granulosa cell tumour (16.7%). This is similar reports from other studies that found adult-type granulosa cell tumour as the commonest tumour in this category [8,27].

Approximately, 1.8% of the tumours in this study were metastatic cancers, much lower than the 8.0% in Bangladesh [12], and the 15.5% reported in Saudi Arabia and the 11.1% in India [18]. In many instances, the primary sources of the ovarian metastatic disease is uncertain, possible malignant tumours include; stomach, breast, renal, lung, uterus and the other pelvic organs [28-30]. However, an important feature of this current study is that two out of the four cases were in females previously diagnosed with advanced adenocarcinoma of the stomach (Krukenberg tumour), both from the pyloric region. This supports reports that the commonest primary source of metastatic ovarian lesion is the gastrointestinal tract particularly cancers involving the pyloric antrum of the stomach [30,31].

Conclusion

The common histological subtypes of ovarian tumours were: germ cell tumours, surface epithelial tumours, sex-cord stroma tumours, metastatic cancers and Burkitt's lymphoma. Significant proportion of the lesions were malignant, an important finding. Ovarian tumours were commonly diagnosed in younger women who presented late with huge intra-abdominal masses. There is the need for detailed investigation of females with non-specific abdominal symptoms for early diagnosis of neoplastic lesions and prompt treatment.

Limitations

- The biggest limitation of this study is the fact that the data was based on a single institution experience and thus open to biases.
- Not all ovarian neoplasm within the catchment of the study was subjected to histopathological examination.

- Being a retrospective review, the data is subjected to all the inherent weaknesses of a study of this kind.

Strength of the study

- This is the first review of ovarian neoplasms in this part of the country Ghana.
- This study was conducted in the largest referral tertiary hospital serving all the five regions in northern Ghana and beyond and thus gives a fair representation of the disease in the population.
- This study may be useful in future for further study of ovarian neoplasm in northern Ghana.

Ethical consideration/informed consent

Permission to write and public the data in this manuscript was granted by the head of department of pathology, the first co-author, Prof. Edmund Muonir Der.

Authors Contributions

D.E.M conceptualised the idea and drafted the manuscript. M.A, A.K, A.S.A and T.A (all obstetricians and gynaecologist), provided the relevant clinical history for all the cases. D.E.M collected and analysed the data. D.E.M, M.A, A.K, A.S.A and T.A did the discussion, read through and approved the manuscript for publication.

Acknowledgement

We thank all workers in the department of Pathology, and the wards, of the various hospital for their assistance in the collection of cases and data for this manuscript.

Reference

1. Bray F, Ferlay J, Siegel LR, et al. GLOBOCAN Estimates of Incidence and Mortality Worldwide for 36 Cancers in 185 Countries. *A Cancer Journal for Clinicians Global Cancer Statistics*. 2018; 68: 394-424
2. Abell MR. The nature and classification of ovarian neoplasms. *Can Med Assoc J*. 1966; 94: 1102-1124.
3. Scully RE. Ovarian tumors A review. *Am J Pathol*. 1977; 87: 686-720.
4. Lee-Jones L. Ovarian tumours: an overview. *Atlas Genet Cytogenet Oncol Haematol*. 2004; 8: 110-114.
5. <https://www.pathologyoutlines.com/topic/ovarytumorwho-classif.html>
6. Wiredu EK, Armah BH. Cancer mortality patterns in Ghana: a 10-year review of autopsies and hospital mortality. *BMC Public Health*. 2006; 6: 159.
7. Nkyekyer K. Pattern of gynaecological cancers in Ghana. *East Afr Med J*. 2000; 77: 534-538.
8. Akakpo PK, Derkyi-Kwarteng L, Gyasi RK, et al. A pathological and clinical study of 706 primary tumours of the ovary in the largest tertiary hospital in Ghana. *BMC Women's Health*. 2017; 17: 34.
9. Der EM, Ibrahim MM, Buunaaim ADB, et al. Baseline Study of Cancer Patterns in the Department of Pathology of the Tamale Teaching Hospital, Northern Region of Ghana. *JAMMR*. 2018; 27: 1-14.
10. Der EM, Seidu S. Case Report of Three Immature Cystic Teratomas in Northern Ghana. *Case Reports in Obstetrics and Gynecology*. 2019; 5.
11. Mondal SK, Banyopadhyah R, Nag DR, et al. Histologic pattern, bilaterality and clinical evaluation of 957 ovarian neoplasms: a 10-year study in a tertiary hospital of eastern India. *J Can Res Ther*. 2011; 7: 433-437.
12. Ahmed M, Afrozeh N, Sabiha M. Morphological Pattern of Ovarian Tumour: Experience in a Tertiary Level Hospital. *J Bangladesh Coll Phys Surg*. 2018; 36: 5-10.
13. Abdullah LS, Bondagji NS. Histopathological pattern of ovarian neoplasms and their age distribution in western region of Saudi Arabia. *Saudi Med J*. 2012; 33: 61-65.
14. Ahmad Z, Kayani N, Hasan SH, et al. Determination of Histological Pattern of Ovarian Neoplasm. *JPMA*. 2000; 50: 416-419.
15. Onyiaorah IV, Anunobi CC, Banjo AA, et al. Histopathological patterns of ovarian tumours seen in Lagos University Teaching Hospital: a ten year retrospective study. *Nig Q Hosp Med*. 2011; 21: 114-118.
16. Bhoola KD, Bhamjee A. A comparative study of ovarian tumours in black and Indian patients. *S Afr Med J*. 1976; 50: 1935-1936.
17. Moorman PG, Palmieri RT, Akushevich L, et al. Ovarian Cancer Risk Factors in African-American and White Women. *Am J Epidemiol*. 2009; 170: 598-606.
18. Rosai J, Ackerman LV. Ovarian tumours in Rosai and Ackerman's Surgical Pathology 10th edition: Mosby. 2008; 1659-1709.
19. Vaidya S, Sharma P, Vaidya SA. Spectrum of ovarian tumour in a referral hospital in Nepal. *Journal of Pathology Nepal*. 2014; 14: 539-543.
20. Tejeswini V, Reddy S, Premalatha P, et al. Study of morphological patterns of ovarian neoplasms. *IOSR journal*. 2013; 10: 11-13.
21. Sharma I, Sharma U, Dutta. Pathology of ovarin tumour- a hospital based study. *International journal of medical science and clinical invention*. 2014; 1: 284-286.
22. Misra RK, Sharma SP, Gupta V, et al. Pattern of ovarian neoplasms in Eastern U.P. *Journal of OBG*. 1991; 241- 246.
23. Abdullahi M, Malami SA, Calvin B, et al. A histo pathological study of ovarian neoplasms in children in a tertiary hospital of northern Nigeria. *AJPS*. 2010; 7: 75-77.
24. Junaid TA. Ovarian neoplasms in children and adolescents in Ibadan, Nigeria. *Cancer*. 1981; 47: 610-614.
25. Young RH, Scully RE. Ovarian sex cord-stromal tumours. Problems in differential diagnosis. *Pathol Annu*. 1988; 23: 273-296.

-
26. Fox H. Sex cord-stromal tumours of the ovary. *J Pathol.* 1985; 145: 127-148.
 27. Colombo N, Parma G, Zanagnolo V, et al. Management of ovarian stromal cell tumours. *J Clin Onc.* 2007; 25: 2944-2951.
 28. Khunamornpong S, Suprasert P, Chiangmai WN, et al. Metastatic tumors to the ovaries: a study of 170 cases in Northern Thailand. *Int J Gynecol Cancer.* 2006; 16: 132-138.
 29. Kanner WA, Galgano MT, Stoler MH, et al. Distinguishing breast carcinoma from mullerian serous carcinoma with mammaglobin and mesothelin. *Int J Gynecol Pathol.* 2008; 27: 491-495.
 30. Al-Agha OM, Nicastrì AD. An in-depth look at Krukenberg tumor: An overview. *Archives of Pathology & Laboratory Medicine.* 2006; 130: 1725-1730.
 31. Kiyokawa T, Young RH, Scully RE. Krukenberg tumors of the ovary: A clinicopathologic analysis of 120 cases with emphasis on their variable pathologic manifestations. *The American Journal of Surgical Pathology.* 2006; 30: 277-299.