

## COMPUTED TOMOGRAPHIC EVALUATION OF POTT'S DISEASE IN TAMALE TEACHING HOSPITAL OF NORTHERN GHANA, 2012 – 2013

*Abdallah Y<sup>1</sup>, Adam A<sup>1</sup>, Alhassan N<sup>1</sup>, and Konlan B<sup>2</sup>*

*1. Tamale Teaching Hospital, 2. UDS*

### Abstract:

*A Retrospective study of Pott's diseases was conducted at the Tamale Teaching Hospital; from January 2012 to December 2013. The highest number of patients was referred from Upper East Region (78%). The disorder was common among women and young adults. Chronic back pain and neuropathy was the frequent presenting complains. The dorsal spine remains the site of preference while L1/L2 recorded the highest incidence. The vertebral body was destroyed in all the cases and the fragmentary type of bone destruction was the common observation. The incidence of cord compression demonstrated by CT was high. Other findings were paraspinal and epidural masses observed in and respectively (Chest Clinic, Tamale Teaching Hospital, Tamale, Ghana).*

**Keywords:** *Potts disease, computed tomography, diagnosis, extra pulmonary tuberculosis, mycobacteria tuberculosis, dissemination, infection, hypo dents*

### BACKGROUND:

Radiological investigations are central in the diagnosis and management of TB spine. In Ghana there is a dearth of literature on the disorder. This paper seeks to describe the CT features of the bony and soft tissue changes in Pott's disease. Retrospective survey revealed that there has been an increase in the number of pott's patients referred from Upper East Region. The patients were important Civil Servants such as Pott's disease is a spinal pathology as a result of atrophy and collapse of the vertebral body.

Policemen, Teachers and students of higher learning institutions. It is therefore empirical to conduct further studies to explain the epidemy of pott's in the Upper East Region of the Northern Ghana.

Of late the treatment success of pott's diseases at the Tamale Teaching Hospital has been recommendable. The method adopted is six months chemotherapy, four months physiotherapy and two months rehabilitation.

### PRESENTATION

- The onset is gradual.
- Back pain is localised.
- Fever, night sweats, anorexia and weight loss.
- Signs may include kyphosis (common) and/or a paravertebral swelling.
- Affected patients tend to assume a protective upright, stiff position.
- If there is neural involvement there will be neurological signs.
- A psoas abscess may present as a lump in the groin and resemble a hernia:
  - A psoas abscess most often originates from a tuberculous abscess of the lumbar vertebra that tracks from the spine inside the sheath of the psoas muscle.
  - Other causes include extension of renal sepsis and posterior perforation of the bowel.
  - There is a tender swelling below the inguinal ligament and they are usually apyrexial.
  - The condition may be confused with a femoral hernia or enlarged inguinal lymph nodes.

## INFECTION AND DISSEMINATION OF TB

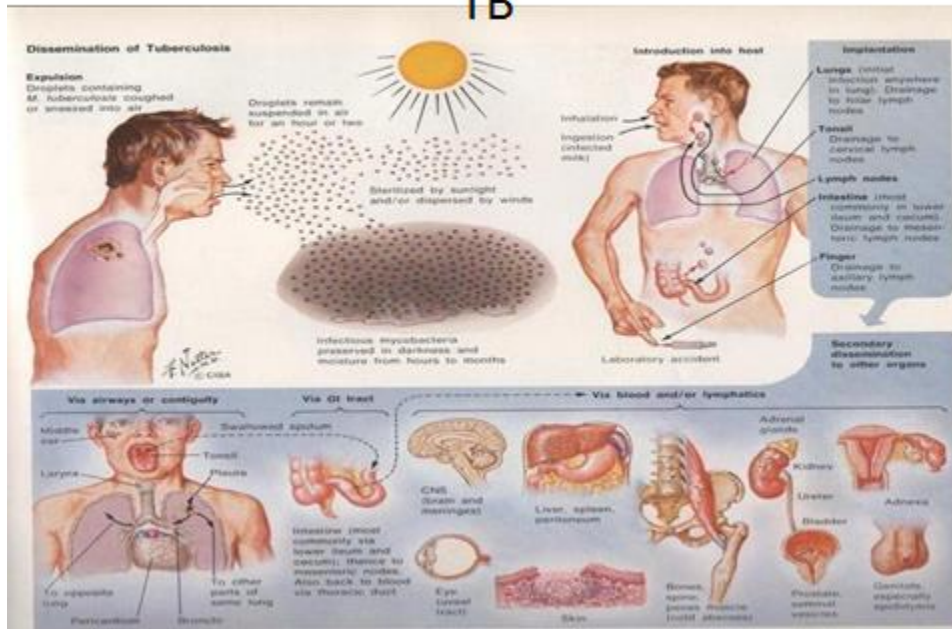


Fig 1: explains the dissemination of tuberculosis to the vertebral column, pathogenesis of Pott’s diseases. (National Center for Biotechnology Information, U.S. National Library of Medicine 8600 Rockville Pike, Bethesda MD, 20894 USA).

### LITERATURE REVIEW

#### Epidemiology

- Pott’s disease is rare in the UK but in developing countries it represents about 2% of cases of tuberculosis and 40 to 50% of musculoskeletal tuberculosis.
- Tuberculosis worldwide accounts for 1.7 billion infections, and 2 million deaths per year.
- Over 90% of tuberculosis occurs in poorer countries, but a global resurgence is affecting richer ones.
- India, China, Indonesia, Pakistan and Bangladesh have the largest number of cases but there has been a marked increase in the number of cases in the former Soviet Union and in sub-Saharan Africa in parallel with the spread of HIV.

- About two thirds of affected patients in developed countries are immigrants, as shown from both London and Paris and spinal tuberculosis may be quite a common presentation.
- The disease affects males more than females in a ratio of between 1.5 and 2:1. In the USA it affects mostly adults but in the countries where it is commonest it affects mostly children.

#### Risk factors

- Endemic tuberculosis.
- Poor socio-economic conditions.
- HIV infection.
- Add notes to any clinical page and create a reflective diary

- Automatically track and log every page you have viewed
- Print and export a summary to use in your appraisal

**After detailed explanation, legal permission was obtained from the patients**

## **METHOD:**

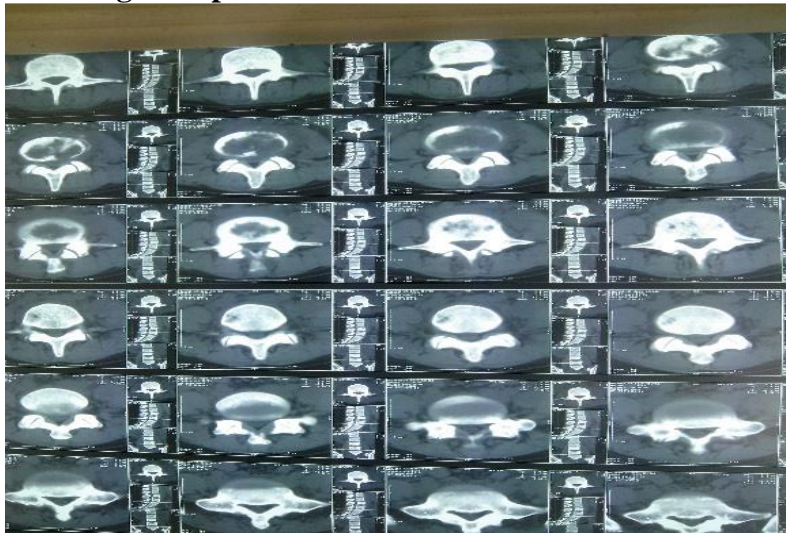It is a descriptive report of the CT scans performed on 30 patients with proven Pott's disease from January 2012 to December 2013 at the Tamale Teaching Hospital in, Ghana.

Retrospective study of radiological survey was done. With the help of demographic records, patients of potts disease were contacted and interviewed. .Clinical record books were reviewed

**ETHICAL CLEARANCE: Was requested and obtained from the Tamale Teaching Hospital Ethical Committee.**

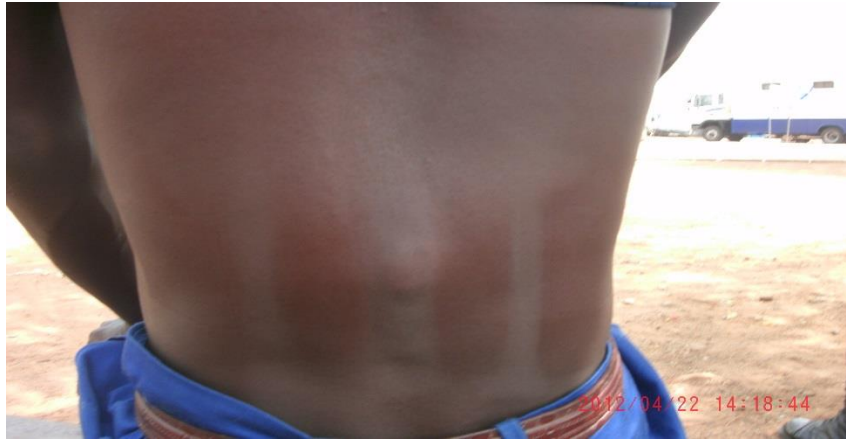## **RESULTS**

The disorder was common among women and young adults (76.7%). Chronic back pain and neuropathy were the frequent presenting complains (53.3%). The dorsal spine remains the site of preference while L1/L2 recorded the highest incidence (73.3%). The vertebral body was destroyed in all the cases and the fragmentary type of bone destruction was the common observation. The incidence of cord compression demonstrated by CT was high (73.3%). Other findings were paraspinal and epidural masses observed in (66.7%) and (73.3%) respectively.



Pic 1

As shown in picture 1; CT of the vertebral column showing distraction of the vertebral body as a result of TB.



Pic 2: first stage of Potts disease/ patient could not walk.

## DISCUSSION

Potts disease is extra pulmonary tuberculosis, which of late has increased in frequency at the chest clinic of the TAMALE Teaching Hospital. As recorded by this research more than 70% of the confirmed Cases were from the upper–east region of Ghana. Further studies will have to be conducted to explain this finding as documented in 2010 at the Teaching Hospital, it was found that delay in intervention after the incubation period, the mycobacteria disseminates to the spinal cord. If immunity compromises, the vertebral body gets hypotrophy, due to intoxication by the pathogen. The failure to absorb calcium, oxygen, vitamin c and vitamin will lead to spondylitis and finally to spinal collapse the spinal collapse causes stenosis which results in the manifestation of ne neurological deficit and to paraparesis (3.). Also as proven in the results more women suffer pots disease than men. Further studies will have to be conducted to explain the phenomenon.

## CONCLUSION:

CT images demonstrated the spinal level of destruction. Improved resolution also showed detailed changes within the outlined soft tissue masses, facilitating early diagnosis and prompt initiation of therapy. More than 70% of the cases were from the Upper east region of the Ghana.

Women and young adults were most vulnerable (76.7%). Chronic back pain and neuropathy were the presenting complains (53.3%)

Further investigation is recommended to explain the epidemiology.

## REFERENCES

1. Aquah et al (2012).The prevalence of tuberculosis at Northern Ghana; A Retrospective review at Tamale Teaching Hospital.
2. Obame et al. (-March 2000) Computed Tomographic Evaluation of Pott's Disease In Accra.
3. Rockville Pike, Bethesda MD, National Center for Biotechnology Information, U.S. National Library of Medicine 8600 20894 USA
4. Yahaya et al (2013).Effect of Delay in intervention on treatment outcome at the chest clinic of Tamale Teaching Hospital.