



Foreign Body Aspiration in Children at the Komfo Anokye Teaching Hospital

**Mawutor Dzogbefia¹, Theophilus Adjeso^{2*}, Duah Mohammed Issahalg¹,
Rita Larsen-Reindorf¹ and Anna Konney¹**

¹Department of Ear, Nose and Throat (ENT), Komfo Anokye Teaching Hospital (KATH), Kumasi, Ghana.

²Department of Eye, Ear, Nose and Throat, School of Medicine and Health Sciences, University for Development Studies, Tamale, Ghana.

Authors' contributions

This work was carried out in collaboration between all authors. All authors read and approved the final manuscript.

Article Information

DOI: 10.9734/JAMMR/2018/45288.

Editor(s):

- (1) Dr. Toru Watanabe, Department of Pediatrics, Niigata City General Hospital, Japan.
(2) Dr. Chan-Min Liu, School of Life Science, Xuzhou Normal University, Xuzhou City, China.

Reviewers:

- (1) J. N. Nwosu, University of Nigeria, Nigeria.
(2) Nahida El-rifai, Beirut Arab University, Lebanon.

Complete Peer review History: <http://www.sciencedomain.org/review-history/28051>

Original Research Article

Received 23 September 2018

Accepted 12 December 2018

Published 01 January 2019

ABSTRACT

Introduction: Foreign body aspiration is a common life threatening event. Foreign bodies in the tracheobronchial tree account for significant morbidity and mortality in children and a high index of suspicion is required for prompt diagnosis

Objectives: To review cases of aspirated foreign bodies in children at the Ear, Nose and Throat (ENT) Department, Komfo Anokye Teaching Hospital (KATH).

Materials and Methods: This was a six-year retrospective study conducted at the ENT Department, KATH. Data evaluated included age, sex, nature of the foreign body, location of the foreign body and outcomes of direct laryngoscopy/bronchoscopy. Data were analyzed with SPSS version 20.

Results: There were 45 cases: 64.4% (n=29) were males giving a male to female ratio of 2:1. Majority of foreign body aspirations occurred in children 3years or below. Aspiration of metallic objects occurred more frequently 9 (20.0%) followed by corn 8 (17.8%) and plastic objects 6

*Corresponding author: E-mail: tadjeso@uds.edu.gh, tadjeso@gmail.com;

(13.3%). Majority of foreign bodies were located in the right main bronchus and there were two failed bronchoscopies.

Conclusion: Foreign body aspiration occurred more frequently in children three years or less and was more common in males. Majority of foreign bodies were located/lodged in the right main bronchus with metallic objects being the most aspirated.

Keywords: Foreign body; aspiration; children; Kumasi; Ghana.

1. INTRODUCTION

Foreign body aspiration is a common life threatening event. Foreign bodies in the tracheobronchial tree account for significant morbidity and mortality in children under the age of three years [1,2]. The sudden inhalation of a foreign body into the respiratory system results in acute respiratory distress, chronic pulmonary infections, atelectasis, and even death [2]. Aspiration of foreign bodies is more common in children because the molar teeth are not developed, and children tend to play or talk with food and small objects in the mouth [1].

In cases of foreign body aspiration, the history is usually suggestive of choking. Clinical symptoms in children who have inhaled foreign bodies include choking episodes and paroxysms of cough. However, the classic clinical presentation of coughing, wheezing, and reduced air entry, is seen in less than 40% of cases. Other symptoms may include cyanoses, fever, and stridor [3].

Large proportions of aspirated foreign bodies are organic in nature, and tend to be mostly food [4]. Prior studies in Ghana show that commonly aspirated foreign bodies include groundnuts, fishbone, seeds, plastic objects and metallic objects [1,5,6]. Studies conducted in Kano and Enugu, Nigeria showed groundnuts and whistles to be the commonly aspirated foreign bodies [7,8].

Unusual foreign bodies such as buttons and stickers may occasionally be encountered in the respiratory tree [9]. The right main bronchus is the commonest location of aspirated foreign bodies.

Management of foreign bodies in the tracheobronchial tree depends on the site of impaction. Glottic or subglottic foreign bodies tend to cause significant airway problems that may require immediate intervention in the form of tracheostomy or bronchoscopy. Conversely, foreign bodies lodged in the right or left main

bronchus cause less significant airway problems [4].

Rigid bronchoscopy under general anaesthesia or heavy sedation is the gold standard for the removal of aspirated foreign bodies. In experienced hands, this procedure is very simple, almost free of complications and mostly successful [3]. The rigid bronchoscope has some distinct advantages over the flexible bronchoscope: The larger diameter of the rigid bronchoscope makes passage of the different grasping devices easier; there is a better chance of grasping foreign bodies, and the ability to suction secretions and blood is enhanced. Flexible bronchoscopy is however less invasive and may be cost effective [10].

This study was conducted to review cases of aspirated foreign bodies at the ENT Department, Komfo Anokye Teaching Hospital, Kumasi Ghana.

2. MATERIALS AND METHODS

This descriptive retrospective review of foreign body aspiration in children was conducted at the Ear, Nose and Throat Department of the Komfo Anokye Teaching Hospital (KATH). KATH is the second largest tertiary referral hospital in Ghana located in Kumasi, the Regional Capital of Ashanti Region of Ghana with a bed capacity of 1200 and catchment population of approximately 4.8 million people (Population Census, 2010). The hospital also receives referrals from Brong Ahafo, Eastern, Western, Central, Northern, Upper East, Upper West and parts of the Volta Regions.

The medical records of all patients managed with direct laryngoscopy/rigid bronchoscopy under general anaesthesia on account of foreign body aspiration from January 2011 to December 2016 in the ENT Department were retrieved. Cases of foreign body aspiration above 15 years were excluded from the study. Extracted data included age, sex, nature of the foreign body, location of

the foreign body and outcomes of direct laryngoscopy/bronchoscopy.

Ethical approval was obtained from the Research and Development Unit of the Komfo Anokye Teaching Hospital.

All extracted data were entered into Microsoft Excel 2010, checked for completeness, cleaned and exported into SPSS version 20 (Chicago, IBM 2010) for descriptive statistical analysis using means, median, standard deviation and frequencies.

3. RESULTS

A total of 45 patients were managed for foreign body aspiration during the study period. There were 29 males (64.4%) with a male to female ratio of 2 :1. The age range was 8 months to 15

years with a mean age of 4.9 ± 3.8 years. Almost half (46.7%) of the cases of foreign body aspiration occurred within the ≤ 3 -year age group (Table 1).

The most common foreign bodies aspirated were metallic objects 9 (20.0%), corn 8 (17.8%) and plastic objects 6 (13.3%) (Table 2).

The foreign bodies were situated in the right main bronchus in 19 (42.2%) patients and in the trachea in 7 (15.6%) patients. Four (8.9%) each of the foreign bodies were located in the larynx, left main bronchus and carina respectively. In 3 (6.7%) instances, the location of the foreign bodies were not documented and in 4 (8.9%) patients no foreign body was visualized during rigid bronchoscopy (Fig. 1). All patients received intravenous dexamethasone 1 mg/kg/day in three divided doses for a maximum of forty-eight hours postoperatively.

Table 1. Age and sex distribution of patients

Age group (years)	Male (N, %)	Female (N, %)	Total (N, %)
0-3	9 (31.0)	12 (75.0)	21(46.7)
4-6	9 (31.0)	2 (12.5)	11(24.4)
7-10	7 (24.1)	1 (6.3)	8(17.8)
11-15	4 (13.8)	1 (6.3)	5(11.1)
Total	29 (64.4)	16 (35.6)	45(100)

Table 2. Nature of foreign body aspirated

Foreign body	Number	Percentage (%)
Bead	1	2.2
Corn	8	17.8
Ear ring	1	2.2
Eraser	1	2.2
Fishbone	2	4.4
Groundnut	2	4.4
Husk of palm	1	2.2
Meat bone	1	2.2
Metallic object	3	6.7
No Foreign bodies	4	8.9
Pen cap	1	2.2
Plaster	1	2.2
Plastic cover	1	2.2
Plastic object	3	6.7
Plastic tube	1	2.2
Screw	2	4.4
Stone	1	2.2
Tape resister	1	2.2
Thumb tacks	1	2.2
Unspecified	6	13.3
Whitish material	2	4.4
Zipper	1	2.2
Total	45	100

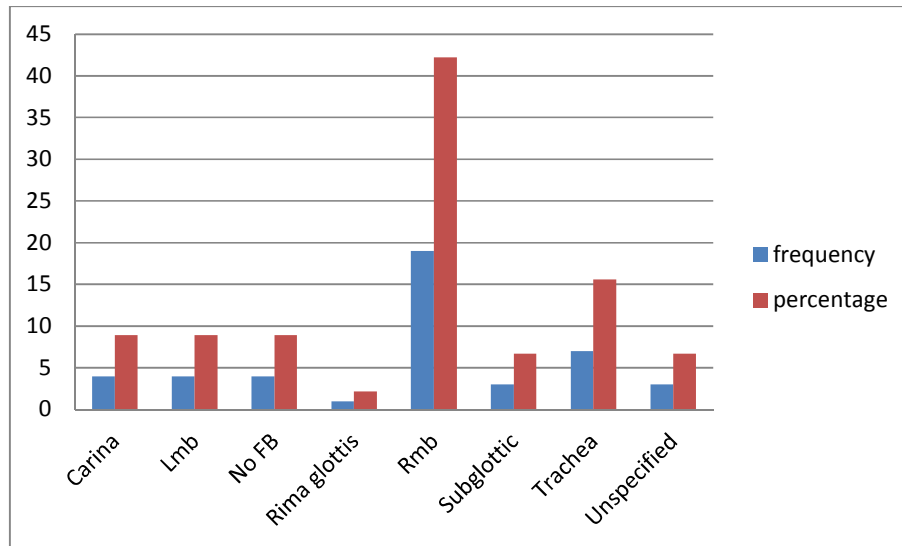


Fig. 1. Location of aspirated foreign body

Lmb: Left main bronchus; No FB: No foreign bodies; Rmb: Right main bronchus

Two (4.4%) children were referred to Korle Bu Teaching Hospital (KBTH) for further treatment on account of failed rigid bronchoscopy.

4. DISCUSSION

This study showed a male (64.4%) preponderance with a male to female ratio of 2 : 1 similar to findings by Saki et al. [4], in their 20-year study of 1015 children in which 63.5% were males and the male to female ratio was 1.73:1.

Male children have generally been considered more adventurous than their female counterparts and this may be one of the reasons for the above observation.

Available literature indicate children below 3 years are the worst victims of foreign body aspiration and the findings of our research is consistent with this fact with 46.7% of the study population found to be 3 years or less. Similar findings have been reported in other studies [4, 11,12] where majority of the cases were 1-3 years. This has been blamed largely on the lack of posterior dentition in children of that age group.

Contrary to the long held view that the foreign bodies (FB) aspirated in developing countries are usually seeds and other organic materials, in our study, metallic objects ranked highest (20%) in the FB aspirated followed by maize seed 17.8% and plastic objects 15.5%. Thus metallic and

plastic objects combined accounted for majority (35.5%) of non-seed foreign bodies aspirated which is in sharp contrast to the findings of Nader Saki et al. who registered majority (63.87%) of foreign bodies aspirated as seeds as against less than 10% for metallic and plastic objects combined.

A similar study conducted in the northern part of the Ghana recorded seeds as the most common foreign bodies aspirated [1]. The difference in findings may be attributable to the fact that KATH serves a more cosmopolitan society as compared to the more traditional/largely rural society of the northern part of Ghana which is largely populated by farmers. Children in the northern part of Ghana are therefore more likely to have easy access to seeds whereas their counterparts in the urban centres may have easy access to old toys with small parts due to unregulated importation of second-hand goods.

In this study, most (42.2%) of the FB aspirated were found lodging at the right main bronchus, followed by the larynx, left main bronchus and carina with frequencies of 15.6%, 8.9%, 8.9% and 8.9% respectively. This is similar to findings [2,12,13] obtained around the globe.

In four patients no foreign body was visualized during rigid bronchoscopy because bronchoscopy was requested for diagnostic purposes to rule out foreign body aspiration since parents of the children could not afford to pay for

a CT scan and X-ray was unremarkable. Two of the patients were referred to KBTH because of lack of requisite instruments to retrieve the foreign body.

The limitation of this study was that poor/incomplete documentation did not allow for analysis of symptom duration, presenting symptoms/signs, time interval to perform bronchoscope as well as hospital stay post-bronchoscopy.

5. CONCLUSION

Foreign Body aspiration is more common in children three years or less and affects more males. Majority of the foreign bodies were lodged in the right main bronchus with metallic objects, corn and plastic objects being the most aspirated foreign bodies. Approximately 96% of the foreign bodies were retrieved successfully with no bronchoscopy associated deaths recorded.

CONSENT

It is not applicable.

ETHICAL APPROVAL

Ethical approval was obtained from the Research and Development Unit of the Komfo Anokye Teaching Hospital.

COMPETING INTERESTS

Authors have declared that no competing interests exist.

REFERENCES

1. Adjeso T, Damah MC, Murphy JP, Teddy T, Anyomih K. Foreign body aspiration in Northern Ghana: A review of paediatric patients. *Int J Otolaryngol*. 2017; 2017:1478795.
2. Yadav SP, Singh J, Aggarwal N, Goel A. Airway foreign bodies in children: experience of 132 cases. *Singapore Med J [Internet]*. 2007; 48(9):850–3. Available:<http://www.ncbi.nlm.nih.gov/pubmed/17728968>
3. Oliveira CF, Almeida JF, Troster EJ, Vaz FA. Complications of tracheobronchial foreign body aspiration in children: Report of 5 cases and review of the literature. *Rev Hosp Clin Fac Med Sao Paulo [Internet]*. 2002;57(3):108–11. Available:<http://www.ncbi.nlm.nih.gov/pubmed/12118268>
4. Saki N, Nikakhlagh S, Rahim F, Abshirini H. Foreign body aspirations in infancy: A 20-year experience. *Int J Med Sci [Internet]*. 2009;6(6):322–8. Available:<http://www.ncbi.nlm.nih.gov/pubmed/19851473>
5. Kitcher ED, Baidoo KK. Audit of inhaled foreign bodies in children: Our recent experience in Ghana. *Niger J Otorhinolaryngol*. 2010;7:12–5.
6. Kitcher ED. Foreign body inhalation: a review of patients at the Korle Bu Teaching Hospital, Accra, Ghana. *West Afr J Med [Internet]*. 2009;28(6):368–70. Available:<http://www.ncbi.nlm.nih.gov/pubmed/20486094>
7. Ahmed AO, Shuiabu IY. Inhaled foreign bodies in a paediatric population at AKTH Kano-Nigeria. *Niger Med J [Internet]*. 2014;55(1):77–82. Available:<http://www.ncbi.nlm.nih.gov/pubmed/24970976>
8. Orji FT, Akpeh JO. Tracheobronchial foreign body aspiration in children: How reliable are clinical and radiological signs in the diagnosis? *Clin Otolaryngol*. 2010; 35(6):479–85.
9. Kansal B, Swamy KM, Ramesh H, Kumar B. Unusual foreign bodies in the respiratory tract of children. *Indian Pediatr*. 2015;52(7).
10. Divisi D, Di Tommaso S, Garramone M, Di Franciscantonio W, Crisci RM, Costa AM, et al. Foreign bodies aspirated in children: Role of bronchoscopy. *Thorac Cardiovasc Surg [Internet]*. 2007;55(4):249–52. Available:<http://www.ncbi.nlm.nih.gov/pubmed/17546556>
11. Boufersaoui A, Smati L, Benhalla KN, Boukari R, Smail S, Anik K, et al. Foreign body aspiration in children: Experience from 2624 patients. *Int J Pediatr Otorhinolaryngol*. 2013;77(10).
12. Sinha V, Chhaya V, Barot DS, Mehta K, Patel P, Patil S, et al. Foreign body in tracheobronchial tree. *Indian J Otolaryngol Head Neck Surg [Internet]*. 2010;62(2):168–70.

- Available:<http://www.ncbi.nlm.nih.gov/pubmed/23120706>
13. Shivakumar AM, Naik AS, Prashanth KB, Shetty KD, Praveen DS. Tracheobronchial foreign bodies. Indian J Pediatr [Internet]. 2003;70(10):793–7. Available:<http://www.ncbi.nlm.nih.gov/pubmed/14649474>

© 2018 Dzogbefia et al.; This is an Open Access article distributed under the terms of the Creative Commons Attribution License (<http://creativecommons.org/licenses/by/4.0>), which permits unrestricted use, distribution, and reproduction in any medium, provided the original work is properly cited.

Peer-review history:
The peer review history for this paper can be accessed here:
<http://www.sciencedomain.org/review-history/28051>